JAMA Pediatrics | Special Communication

International Consensus Statement on the Radiological Screening of Contact Children in the Context of Suspected Child Physical Abuse

Kshitij Mankad, MD; Jai Sidpra, BSc (Hons); David M. Mirsky, MD; Adam J. Oates, PhD; Gabrielle C. Colleran, MD; Leandro T. Lucato, PhD; Elaine Kan, MD; Tracy Kilborn, MD; Nina Agrawal, MD; Arianne H. Teeuw, PhD; Patrick Kelly, MD; Deborah Zeitlin, MD; Jamieson Carter, MD; Geoff D. Debelle, MD; Rachel P. Berger, MPH; Cindy W. Christian, MD; Daniel M. Lindberg, MD; Maria Raissaki, PhD; Maria Argyropoulou, MD; Catherine Adamsbaum, MD; Timothy Cain, MD; Rick R. van Rijn, PhD; V. Michelle Silvera, MD; Andrea Rossi, MD; Alison M. Kemp, MD; Arabinda K. Choudhary, MD; Amaka C. Offiah, PhD

IMPORTANCE Physical abuse is a common but preventable cause of long-term childhood morbidity and mortality. Despite the strong association between abuse in an index child and abuse in contact children, there is no guidance outlining how to screen the latter, significantly more vulnerable group, for abusive injuries. Consequently, the radiological assessment of contact children is often omitted, or variably performed, allowing occult injuries to go undetected and increasing the risk of further abuse.

OBJECTIVE To report an evidence-based and consensus-derived set of best practices for the radiological screening of contact children in the context of suspected child physical abuse.

EVIDENCE REVIEW This consensus statement is supported by a systematic review of the literature and the clinical opinion of an internationally recognized group of 26 experts. The modified Delphi consensus process comprised 3 meetings of the International Consensus Group on Contact Screening in Suspected Child Physical Abuse held between February and June 2021.

FINDINGS Contacts are defined as the asymptomatic siblings, cohabiting children, or children under the same care as an index child with suspected child physical abuse. All contact children should undergo a thorough physical examination and a history elicited prior to imaging. Contact children younger than 12 months should have neuroimaging, the preferred modality for which is magnetic resonance imaging, and skeletal survey. Contact children aged 12 to 24 months should undergo skeletal survey. No routine imaging is indicated in asymptomatic children older than 24 months. Follow-up skeletal survey with limited views should be performed if abnormal or equivocal at presentation. Contacts with positive findings should be investigated as an index child.

CONCLUSIONS AND RELEVANCE This Special Communication reports consensus recommendations for the radiological screening of contact children in the context of suspected child physical abuse, establishing a recognized baseline for the stringent evaluation of these at-risk children and providing clinicians with a more resilient platform from which to advocate for them.

Supplemental content

Author Affiliations: Author affiliations are listed at the end of this article.

Corresponding Author: Kshitij Mankad, MD, Department of Neuroradiology, Great Ormond Street Hospital for Children NHS Foundation Trust, Great Ormond Street, London, WC1N 3JH, United Kingdom (drmankad@gmail.com).

JAMA Pediatr. 2023;177(5):526-533. doi:10.1001/jamapediatrics.2022.6184
Published online March 6, 2023.

© 2023 American Medical Association. All rights reserved.

Downloaded From: https://edhub.ama-assn.org/ by University of Texas - Rio Grande Valley, Stanley Fisch on 06/01/2023

Physical abuse, defined as the neglectful, intentional, or reckless use of force against a child that causes or has the potential to cause physical injury, is a significant yet preventable cause of long-term childhood morbidity and mortality (prevalence, 4% to 20%).[1-8] As evidenced in perpetrator confessions, early detection of child physical abuse is protective due to its escalating nature.[9-11] However, this is difficult to achieve given the significant number of abusive injuries that remain occult despite physical examination.[12] Even in children with examination findings, severe abusive injuries, including abusive head trauma (AHT), may remain occult.[13,14] Therefore, comprehensive evaluation of the contacts of children who experience abuse should be undertaken regardless of the form of abuse, particularly since the same type of abuse tends to recur between siblings.

The Need for Consensus

Radiological screening of high-risk populations can increase the detection of occult injuries and initiate appropriate intervention.[15] The best characterized of these high-risk groups are the contacts—ie, the siblings, cohabiting children, and children under the same care—of an index child presenting with suspected or confirmed physical abuse. Numerous observational studies report an increased prevalence of physical abuse in the contacts of children who experience abuse, with abuse directed toward all children rather than solely toward the index child in up to 37% of cases.[15-20] Multiple-birth siblings are at greatest risk of concomitant abuse and are at particularly high risk of positive findings on radiological screening for occult injury.[17,18,20]

Despite the strong association between physical abuse in an index child and in contact children, there is a lack of guidance and consensus on the radiological evaluation of contact children.[14,17,21] In the absence of this guidance, rates of clinical and radiological screening are highly variable, and published surveys of child abuse pediatricians report disparate and/or incomplete assessment of contact children in up to 40% of cases.[15,22,23] Even in centers that accept contact screening as a standard of care, screening is not completed in a significant proportion of children (approximately 24%), often due to resistance by frontline medical professionals.[17] This worrying clinical heterogeneity risks unstructured decision-making, missed diagnoses, and the perpetuation of physical abuse.[21]

The World Health Organization has identified the need for clear, accessible guidelines for the early detection of physical abuse as pivotal to the prevention of child maltreatment.[6] With this goal in sight, our group proposed a guideline for sibling screening in the context of suspected AHT.[24] We now build on this work via an established consensus group and, based on a review of the literature and our collective clinical experience, outline a standardized international consensus protocol for the radiological screening of contact children in the context of suspected physical abuse.

Current Guidelines

The American College of Radiology Appropriateness Criteria for suspected child physical abuse notes that "pediatric contacts of abused children may also need to be screened by skeletal survey"[25] but offers no guidance on which contacts would benefit most from screening or on how and when screening should be performed. Similarly, a recent consensus statement on AHT, endorsed by numerous international societies, makes no mention of contact children.[26] Guidelines from the Royal College of Radiologists and Royal College of Paediatrics and Child Health (later adopted by the European Society of Paediatric Radiology[27]) are more comprehensive, recommending that "any multiple birth sibling(s) of an index case less than two years of age should have the same recommended imaging as the index case [and that] age-appropriate imaging should be considered in all siblings and children less than two years old living in the same household or in the household of the alleged or suspected perpetrator(s) on a case-by-case basis."[28] This, therefore, does not consider children aged 2 to 5 years and remains vague with regards to which imaging modalities should be used for screening. Given this variation, there is a strong mandate for standardization.

Methods

Literature Review

PubMed was systematically searched for articles reporting (1) radiological protocols for the investigation of suspected child physical abuse and (2) radiological findings in the contacts of index children with suspected physical abuse. Search methodology is reported in the eMethods in the Supplement. Literature review confirmed a lack of guidance on the radiological screening of contact children and informed the construction of each consensus statement.

Consensus Process

This consensus statement is derived from 3 meetings of the International Consensus Group on Contact Screening in Suspected Child Physical Abuse, a panel of 26 experts invited to participate in this modified Delphi consensus process.[29] Participating board-certified (or equivalent) experts included 9 child abuse pediatricians, 9 pediatric radiologists, 7 pediatric neuroradiologists, and 1 emergency medicine physician with a minimum postqualification experience of 10 years in the management of children with suspected physical abuse. Delphi panelists are listed in the eAppendix in the Supplement.

Meetings were held on February 26, March 5, and June 11, 2021. Preceding each meeting, experts voted electronically on a series of consensus statements. The first round of consensus statements was informed by literature review and a survey of the Delphi panel aiming to (1) gauge the clinical need for consensus and (2) define areas of greatest discrepancy and uncertainty. All Delphi participants reviewed identical literature, as defined above. During meetings, the panel discussed consensus statements and agreed on new or modified recommendations for the radiological screening of contact children. Consensus statements were subsequently accepted or revised and the process iterated until consensus achieved. Results from Delphi rounds are available in eResults 1 in the Supplement. Following Delphi rounds, the consensus document was internally reviewed and endorsed by all panel members prior to external review by 8 internationally recognized child abuse pediatricians (eAppendix in the Supplement). The outcome of external consultation on each consensus statement is available in eResults 2 in the Supplement. Consultation recommendations and the revised consensus statement were reviewed, discussed, and endorsed by all authors.

Consensus was defined as 80% or more agreement. Unless otherwise stated, we report recommendations exceeding this level of consensus.

© 2023 American Medical Association. All rights reserved.

Downloaded From: https://edhub.ama-assn.org/ by University of Texas - Rio Grande Valley, Stanley Fisch on 06/01/2023

Figure. Consensus Guideline for the Screening of Contacts of Index Children With Suspected Child Physical Abuse

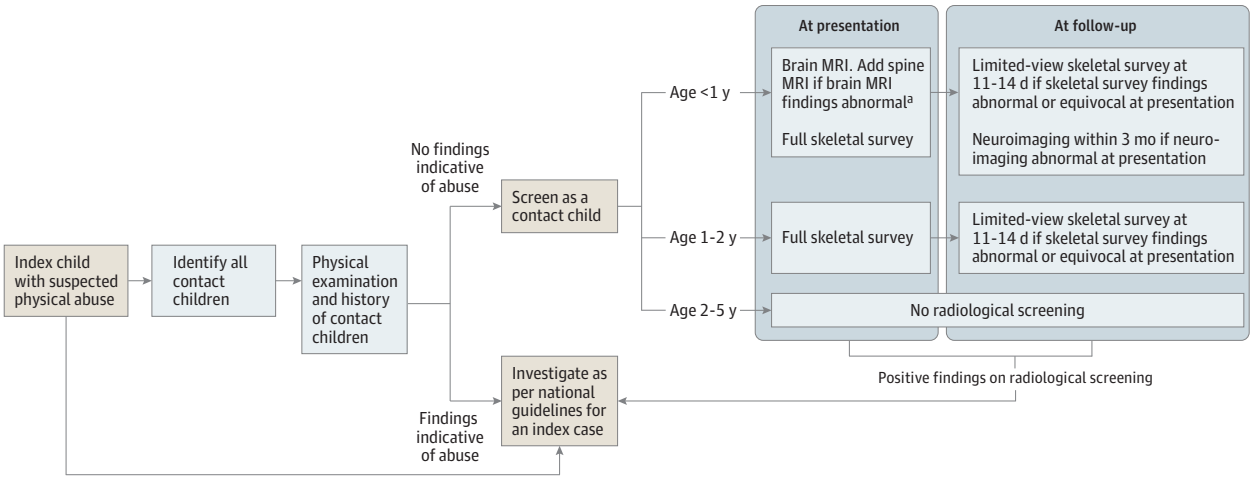

[a] Head computed tomography may be performed if magnetic resonance imaging (MRI) is unavailable.

Consensus Recommendations

This consensus statement should be applied for the radiological screening of asymptomatic contact children younger than 5 years secondary to the presentation of an index child with suspected physical abuse. Index children are defined as children presenting with signs and/or symptoms of suspected physical abuse, most of whom are younger than 2 years.[28] Irrespective of findings in the index case, once the threshold for investigation is reached, all contact children should be screened as outlined. Contacts are defined as the asymptomatic siblings, cohabiting children, or children under the same care as an index child with suspected physical abuse. Screening applies only to asymptomatic contacts; contacts with signs and/or symptoms of physical abuse should be investigated as an index case. Hence, in the first instance, all contact children should undergo thorough physical examination, with careful attention paid to the skin, ears, oropharynx, genitalia, and growth parameters to confirm the absence of physical signs indicative of abuse.[30-32] A clinical history should also be elicited using age-appropriate techniques tailored to the child's speech and cognitive abilities.[30]

Despite being more common in children younger than 2 years, physical abuse is a dynamic entity, with different patterns of injury at different ages reflecting the unique physical vulnerabilities of the developing child.[17,33,34] In consequence, we recommend an age-stratified and, by virtue, a risk-stratified approach to screening contact children for physical abuse, with younger children undergoing more intensive investigation, as summarized in the **Figure**.

Standardized Screening Skeletal Survey

Radiographic skeletal survey is the optimal modality for investigating potential fractures in children.[35] At ascertainment, a full skeletal survey should be performed for all contact children younger than 2 years, as established in the protocol in **Table 1**.[28,35] Radiographs should be coned to the area of interest and specific views acquired.[25,28] Inclusion of coned views of the joints may be dependent on national guidance.[25] Suspected fractures equivocal on the initial skeletal survey should be further evaluated with additional projections, follow-up skeletal survey, and/or computed tomography (CT).[21,25,28,36] A multicenter observational cross-sectional study reports the yield of skeletal survey for abusive injuries in contact children younger than 2 years as 9.4% to 11.9%, with twin contact children significantly more likely than nontwin contact children to have a fracture identified on skeletal survey.[15,17]

We do not recommend routine screening skeletal survey in contact children aged 24 to 36 months despite similar rates of fracture identification on skeletal survey in children aged 12 to 24 months (12.0%) and 24 to 36 months (10.3%) in a multicenter observational study of 2609 index children younger than 60 months evaluated for suspected physical abuse, with comparable yields replicated in other, smaller studies.[37-41] This is because of the rapid development of a child's verbal abilities during this time and, with this, the increasing ability of the child to self-report trauma, pain, and other symptoms indicative of abusive fractures.[42] This ability to self-report, in combination with the need to minimize radiation exposure in young children, as per the as low as reasonably achievable (ALARA) principle, mitigates the need for ipso facto radiological screening in favor of clinical screening.[43] However, the physician should have a lower threshold to perform a skeletal survey in contact children up to age 36 months based on the developmental stage of the contact child and the injuries sustained by the index child. Contact children aged 3 to 5 years should not undergo skeletal survey given the significantly lower likelihood of detecting occult fractures, unless in exceptional circumstances—namely, if children are unable to self-report injuries, as may be the case with certain neurodisabilities or neurodevelopmental disorders, or if children have medical conditions that predispose to fractures.[44]

Neuroimaging of the Contact Child

When imaging an asymptomatic contact child, the physician must balance the protective benefits of detecting occult head injury with the risks of radiation and sedation. We recommend neuraxial magnetic resonance imaging (MRI) at 1.5T or 3.0T over CT as the pre-

© 2023 American Medical Association. All rights reserved.

Downloaded From: https://edhub.ama-assn.org/ by University of Texas - Rio Grande Valley, Stanley Fisch on 06/01/2023

ferred screening modality given the absence of ionizing radiation and greater soft tissue resolution.[45-47]

Although CT is the optimal modality for skull fracture detection, MRI is the most sensitive modality for identification of the low-volume extra-axial (subdural) hemorrhages, parenchymal injuries, cerebral edema, and spinal ligamentous injuries commonly seen in AHT.[26,48,49] Several studies have described children with occult AHT and normal findings on head CT but abnormal findings on brain MRI.[50,51] In the study by Boehnke et al[51] of 714 neurologically intact index children younger than 2 years investigated for suspected physical abuse, 100 underwent both CT and MRI, of whom 5 (5%) had imaging findings suggestive of AHT detectable on MRI but undetectable on CT. Advanced sequences, such as diffusion-weighted imaging and susceptibility-weighted imaging, further increase the sensitivity for diffuse axonal injury, cerebral microhemorrhage, and retinal hemorrhage.[48,52,53] Given the existence of conditions that may mimic AHT and the significant medicolegal implications of a diagnosis, MRI also helps exclude some differential diagnoses.[54]

Fast MRI, defined as the acquisition of motion-tolerant sequences in a nonsedated child, has been proposed as an alternative to CT for the screening of clinically stable infants with traumatic brain injury.[47] Although sensitive for intracranial hemorrhage and soft tissue injuries, the limited sequences by protocol—in particular, the omission of spinal sequences—renders it less sensitive than both noncontrast CT and standard MRI when imaging an asymptomatic contact child with occult AHT.[55] In, to our knowledge, the only study reporting the diagnostic accuracy of fast MRI compared with standard MRI, Kralik et al[55] retrospectively evaluated 24 children with suspected AHT, reporting a decreased interobserver reliability for fast MRI compared with standard MRI as well as a lower sensitivity (50%) and negative predictive value (31%) of fast MRI compared with standard MRI for findings indicative of intracranial trauma. Thus, the increased sensitivity of standard MRI justifies the potential need for sedation in some children.[56] The yield of screening neuroimaging is unknown given the overly restrictive threshold criteria at which neuroimaging is performed in current studies, precluding extrapolation and estimation of the true incidence of AHT in contact children.[15,17]

Standardized Screening Craniospinal MRI Protocol

Contact children younger than 1 year should undergo brain MRI, unless in exceptional circumstances. Imaging of the whole spine should be performed in the same session if brain imaging findings are abnormal, given the forensically valuable information provided by spinal MRI, including suggestion of potential injury mechanisms, further evidence of trauma in the setting of nonspecific intracranial findings, and identification of additional injuries inconsistent with the presenting history, particularly given the high sensitivity of spinal injuries for an abusive rather than accidental etiology.[49,50,57-60] MRI of the whole spine is recommended, as isolated thoracolumbar injuries are commonly seen in children with AHT.[60] Spinal MRI is not recommended in contact children with normal brain imaging findings because spinal injuries, in particular, ligamentous injuries and spinal subdural hemorrhage, very rarely present without brain findings, alter clinical management, or persist beyond the acute phase (rendering yield low in an asymptomatic population).[49,60] Contact children older than 1 year should not undergo neuroimaging for screening purposes, unless in exceptional circumstances.

Table 1. Recommended Skeletal Survey for the Assessment of Contacts of Children With Suspected Child Physical Abuse

Region	Views	Comments
Axial skeleton		
Skull[a]	AP; lateral	None
Spine[a]	Lateral	For children <1 y, it may be possible to obtain 1 radiograph; for larger children and for children >1 y, 2 separate views may be required of (1) the cervicothoracic spine and (2) the lumbosacral spine
Thorax	AP; right oblique view of the ribs; left oblique view of the ribs	AP to include the clavicles; oblique to include all ribs (1-12) and both sides (right and left)
Pelvis[a]	AP	To include the midlumbar spine
Appendicular skeleton		
Limbs		
Upper	AP humeri; AP forearms; PA hands; coned lateral elbows; coned lateral wrists; coned PA wrists	Bilateral
Lower	AP femora; AP lower legs; DP feet; coned AP knees; coned lateral knees; coned AP ankles; coned lateral ankles	Bilateral

Abbreviations: AP, anteroposterior; DP, dorsoplantar; PA, posteroanterior.

[a] Radiographs should be omitted from the follow-up skeletal survey.

The standardized brain and whole-spine MRI protocol for contact screening is presented in **Table 2**.[49] A combination of simple and advanced sequences safely maximizes the yield of the study while minimizing study duration and ensuring the protocol is achievable in most children younger than 1 year without the need for sedation.[61] The inclusion of specific sequences may be dependent on national guidance. Inclusion of a T2-weighted fluid-attenuated inversion recovery (FLAIR) sequence is optional, having reached 68.75% agreement in the final Delphi round. The rationale for this is 2-fold: (1) there are no data on the relative yield of T2 FLAIR for the detection of subdural hemorrhage in MRI studies that, by protocol, include T1-weighted and T2-weighted sequences despite anecdotal evidence suggesting high sensitivity for small subdural hemorrhage and parenchymal injuries and (2) the relatively long acquisition time of T2 FLAIR increases scan time and the potential need for sedation.[48,62-64]

Imaging Guideline Adaptations and Further Considerations

The challenges of imaging contact children vary depending on (1) management of the index child and (2) resource availability, given the expense of additional imaging and the cost and risk of sedation, if required. The principal adaptation to this consensus statement is for clinical settings without routine access to MRI, in which we recommend contact children undergo a CT scan of the head with 3-dimensional reconstructions in an identical, age-appropriate manner to MRI. CT may also be performed in adjunct to MRI if concerns persist surrounding the presence of an isolated skull fracture, which may raise the suspicion for abuse or an anatomical variant, either of which may alter management.[65,66]

Although contact children should be imaged as soon as possible, it is acceptable to delay imaging for up to 7 days following presentation of the index child. This may be unavoidable if the index child presents out of hours, at which time access to MRI is delayed for the contact child. If imaging is delayed, contact children should

© 2023 American Medical Association. All rights reserved.

Downloaded From: https://edhub.ama-assn.org/ by University of Texas - Rio Grande Valley, Stanley Fisch on 06/01/2023

Table 2. Recommended Magnetic Resonance Imaging Sequences and Parameters for the Assessment of Contacts of Children With Suspected Child Physical Abuse

Sequence	Slice thickness, mm	Gap, %	In-plane resolution, mm	Plane	Scan time, min:s
Brain: mandatory					
1. 3-D T1-weighted fast-field echo or turbo-field echo	1.0-1.2	0	1.0 × 1.0 × 1.0 isotropic voxel resolution	Axial acquisition; coronal and sagittal reformats	4:30
2. T2-weighted 2-D spin echo, turbo-spin echo, or fast-spin echo	≤4.0	0	≤1.0 × 1.0	Axial	3:05
3. SWI	≤2.0	0	NA	Axial	3:48
4. DWI (b = 0 and b = 1000) with ADC 2-D echo-planar imaging	≤4.0	0	2.0 × 2.0	Axial	2:48
Brain: optional					
5. T2-weighted FLAIR 2-D turbo-spin echo or fast-spin echo	≤4.0	0	≤1.0 × 1.0	Coronal	4:02
Whole spine					
1. T2-weighted STIR, fat saturated, or Dixon	≤3.0	0	Minimum matrix frequency of 256 voxels	Sagittal	3:40
2. T1-weighted 2-D turbo-spin echo or fast-field echo	≤3.0	0	Minimum matrix frequency of 256 voxels	Sagittal	2:11

Abbreviations: 2-D, 2-dimensional; 3-D, 3-dimensional; ADC, apparent diffusion coefficient; DWI, diffusion-weighted imaging; FLAIR, fluid-attenuated inversion recovery; NA, not applicable; STIR, short tau inversion recovery; SWI, susceptibility-weighted imaging.

be kept in a place of safety to remove doubt as to the chronicity of potential findings.

A final caveat is that imaging may be indicated outside of the age ranges recommended in this consensus statement in the sole instance that evidence is produced during an investigation that raises the possibility of prior traumatic injury to the head or skeleton in a now asymptomatic, older contact child.

Standardized Screening CT Head Protocol

If performed as the primary screening modality, we recommend contact children undergo a low-dose noncontrast CT head (slice thickness of 1 mm or less), from the vertex to the skull base. Multiplanar 3-dimensional reconstructions in bone and soft kernel should be performed to increase the diagnostic accuracy of skull fractures and intracranial hemorrhage.[67,68] Given the greater sensitivity and specificity of 3-dimensional–reconstructed CT head for skull fractures, skull radiographs should be omitted from the skeletal survey if a head CT is performed as the primary neuroimaging modality.[69]

Spinal CT is not recommended as it is less sensitive than MRI, particularly for the identification of occipitocervical ligamentous injuries.[57,58] If findings from a screening head CT are positive, spinal MRI should be considered for completeness.

Follow-up Imaging

Follow-up skeletal surveys are not mandatory for contact screening, as asymptomatic children are likely to have experienced historic abuse with older, occult fractures identified on the first skeletal survey.[17] Thus, we recommend that a follow-up skeletal survey with limited views is considered on a case-by-case basis for contact children younger than 2 years and is performed routinely if the first skeletal survey is abnormal or equivocal. Although the yield of follow-up skeletal survey is unknown in both index and contact children, it increases diagnostic sensitivity and specificity, aids identification of previously radiographically occult fractures, and assists injury dating.[25,28,70] If indicated, follow-up skeletal survey should be performed within 11 to 14 days and no later than 28 days after the first skeletal survey. The specificity of this time frame is 2-fold: (1) the earliest calcified periosteal reaction seen at neonatal fracture sites is at 7 days and (2) some fractures, in particular thin bucket-handle metaphyseal fractures, may heal completely after 14 to 21 days.[71,72] Limited views suffice for follow-up skeletal survey, as they confer a lower radiation dose and have no significant difference in fracture detection.[36,73] If neuroimaging yields positive findings in a contact child, follow-up neuroimaging should be performed within 3 months as per national guidelines for the management of index children with suspected AHT.[64]

Future Work

Our framework offers the vital first steps toward a standardized, internationally adopted, evidence-based guideline for the screening of these at-risk children. The main limitation of our work is the lack of literature reporting the yield of neuroimaging and follow-up skeletal surveys in contact children. This is, in part, due to inadequate implementation of contact screening but also due to the inherent difficulties of studying child physical abuse, with the vast majority of evidence derived from retrospective observational studies and with no comparative multinational prospective studies.[2,74]

Following adoption by our group, this consensus statement will provide the recognized baseline for a planned prospective multinational, multicenter study on the prevalence and distribution of abusive injuries in contact children. The additional insights provided will permit evidence-based adjustments to this guideline and will significantly further our epidemiological knowledge of how physical abuse affects children around the world.

Conclusions

Radiological screening plays a central role in the multidisciplinary identification of suspected and occult abusive injuries. It is our hope that this international consensus statement will provoke a shift in clinical practice such that the routine screening of contact children

© 2023 American Medical Association. All rights reserved.

Downloaded From: https://edhub.ama-assn.org/ by University of Texas - Rio Grande Valley, Stanley Fisch on 06/01/2023

is incorporated as a standard of care reflective of society's obligation to the young and vulnerable, providing clinicians with a more resilient platform from which to advocate not only for the index child but for all at-risk children.

ARTICLE INFORMATION

Accepted for Publication: December 14, 2022.

Published Online: March 6, 2023. doi:10.1001/jamapediatrics.2022.6184

Author Affiliations: Department of Neuroradiology, Great Ormond Street Hospital for Children NHS Foundation Trust, London, United Kingdom (Mankad, Sidpra); Developmental Biology and Cancer Section, University College London Great Ormond Street Institute of Child Health, London, United Kingdom (Mankad, Sidpra); Department of Radiology, Children's Hospital Colorado, University of Colorado School of Medicine, Aurora (Mirsky); Department of Radiology, Birmingham Children's Hospital, Birmingham, United Kingdom (Oates); Department Radiology, Children's Health Ireland and The National Maternity Hospital, Dublin, Ireland (Colleran); Department of Radiology, Universidade de São Paulo, Faculdade de Medicina, São Paulo, Brazil (Lucato); Department of Radiology, Hong Kong Children's Hospital, Hong Kong (Kan); Department of Radiology, Red Cross War Memorial Children's Hospital, University of Cape Town, Cape Town, South Africa (Kilborn); City University of New York Graduate School of Public Health and Health Policy, New York (Agrawal); Department of Pediatrics, Emma Children's Hospital–Amsterdam UMC, University of Amsterdam, Amsterdam, the Netherlands (Teeuw); Te Puaruruhau, Starship Children's Health, Auckland, New Zealand (Kelly); Department of Pediatrics: Child and Youth Health, Faculty of Medical and Health Sciences, University of Auckland, Auckland, New Zealand (Kelly); Department of Pediatrics, Great Ormond Street Hospital for Children NHS Foundation Trust, London, United Kingdom (Zeitlin); Department of Pediatrics, Brighton and Sussex Medical School, Brighton, United Kingdom (Carter); Department of Pediatrics, Birmingham Children's Hospital, Birmingham, United Kingdom (Debelle); Department of Pediatrics, UPMC Children's Hospital of Pittsburgh, Pittsburgh, Pennsylvania (Berger); Department of Pediatrics, The Children's Hospital of Philadelphia, The Perelman School of Medicine at the University of Pennsylvania, Philadelphia (Christian); Department of Emergency Medicine, University of Colorado School of Medicine, Aurora (Lindberg); Department of Radiology and Imaging, University Hospital of Heraklion, Medical School, University of Crete, Rethymno, Greece (Raissaki); Department of Clinical Radiology, School of Health Sciences, Faculty of Medicine, University of Ioannina, Ioannina, Greece (Argyropoulou); Paris Saclay University, Faculty of Medicine, AP-HP, Bicêtre Hospital, Department of Paediatric Radiology, Le Kremlin Bicêtre, France (Adamsbaum); Department of Medical Imaging, Royal Children's Hospital Melbourne, Parkville, Australia (Cain); Department of Radiology and Nuclear Medicine, Emma Children's Hospital–Amsterdam UMC, University of Amsterdam, Amsterdam, the Netherlands (van Rijn); Department of Forensic Medicine, Netherlands Forensic Institute, The Hague, the Netherlands (van Rijn); Department of Radiology, Mayo Clinic, Rochester, Minnesota (Silvera); Neuroradiology Unit, IRCCS Istituto Giannina Gaslini, Genoa, Italy (Rossi); Department of Health Sciences, University of Genoa, Genoa, Italy (Rossi); Division of Population Medicine, Department of Child Health, University of Cardiff, Cardiff, United Kingdom (Kemp); Department of Radiology, University of Arkansas for Medical Sciences, Little Rock (Choudhary); Department of Radiology, Sheffield Children's Hospital NHS Foundation Trust, Sheffield, United Kingdom (Offiah); Department of Oncology and Metabolism, University of Sheffield, Sheffield, United Kingdom (Offiah).

Author Contributions: Dr Mankad and Mr Sidpra had full access to all of the data in the study and take responsibility for the integrity of the data and the accuracy of the data analysis. Dr Mankad and Mr Sidpra contributed equally to this work.
Study concept and design: Mankad, Sidpra, Mirsky, Oates, Kan, Adamsbaum, Offiah.
Acquisition, analysis, or interpretation of data: Mankad, Sidpra, Oates, Colleran, Lucato, Kan, Kilborn, Agrawal, Teeuw, Kelly, Zeitlin, Carter, Debelle, Berger, Christian, Lindberg, Raissaki, Argyropoulou, Cain, van Rijn, Silvera, Rossi, Kemp, Choudhary, Offiah.
Drafting of the manuscript: Mankad, Sidpra, Oates, Colleran, Lucato, Kan, Carter, Adamsbaum, van Rijn, Offiah.
Critical revision of the manuscript for important intellectual content: Mankad, Sidpra, Mirsky, Oates, Lucato, Kan, Kilborn, Agrawal, Teeuw, Kelly, Zeitlin, Carter, Debelle, Berger, Christian, Lindberg, Raissaki, Argyropoulou, Adamsbaum, Cain, van Rijn, Silvera, Rossi, Kemp, Choudhary, Offiah.
Statistical analysis: Mankad, Sidpra.
Administrative, technical, or material support: Mankad, Sidpra, Oates, Colleran, Lucato, Christian, Cain.
Study supervision: Mankad, Sidpra, Oates, Kilborn, van Rijn, Rossi, Choudhary, Offiah.

Conflict of Interest Disclosures: Drs Mankad, Oates, Debelle, Christian, Lindberg, Adamsbaum, Rossi, and Offiah provide private medicolegal expertise on instruction by the court. Dr Mankad has received personal fees from Cromwell Hospital, HCA UK, European Society of Paediatric Neuroradiology, and UK Crown Court and acts as the Chair of the British Paediatric Neuroimaging Group outside the submitted work. Mr Sidpra has received grants from Cancer Research UK as well as personal fees from University College London and Cancer Research UK outside the submitted work. Dr Mirsky acts as Vice President of the American Society of Pediatric Neuroradiology. Dr Lindberg received grant funding from the Eunice Kennedy Shriver National Institute of Child Health and Human Development, US Department of Defense, Colorado Crime Victims Services Fund, and Colorado Traumatic Brain Injury Trust Fund. Dr Raissaki is co-chair of the European Society of Paediatric Radiology Child Abuse Taskforce. Dr Argyropoulou is a member of the European Society of Pediatric Radiology Child Abuse Taskforce. Dr Silvera acts as President of the American Society of Pediatric Neuroradiology. Dr van Rijn has received royalties from Springer and Thieme outside the submitted work. Dr Rossi has received personal fees from Bracco Imaging, Merck, Nestlè, and Telemedicine Clinic outside the submitted work and acts as the President of the Italian Association of Neuroradiology and as Secretary General of the European Society of Neuroradiology. Dr Offiah has received personal fees from College of Policing, European College of Radiology, and InfoMed outside the submitted work; is chairperson of the European Society of Paediatric Radiology's Child Abuse Taskforce; and is Managing Editor of *Pediatric Radiology*. No other disclosures were reported.

REFERENCES

1. Keenan HT, Runyan DK, Marshall SW, Nocera MA, Merten DF, Sinal SH. A population-based study of inflicted traumatic brain injury in young children. *JAMA*. 2003;290(5):621-626. doi:10.1001/jama.290.5.621

2. Gilbert R, Widom CS, Browne K, Fergusson D, Webb E, Janson S. Burden and consequences of child maltreatment in high-income countries. *Lancet*. 2009;373(9657):68-81. doi:10.1016/S0140-6736(08)61706-7

3. Leeb RT, Paulozzi LJ, Menanson C, Simon TR, Arias I. *Child Maltreatment Surveillance: Uniform Definitions for Public Health and Recommended Data Elements*. National Center for Injury Prevention and Control; 2008.

4. Parks S, Annest J, Hill H, Karch D. *Pediatric Abusive Head Trauma: Recommended Definitions for Public Health Surveillance and Research*. National Center for Injury Prevention and Control; 2012.

5. Goldstick JE, Cunningham RM, Carter PM. Current causes of death in children and adolescents in the United States. *N Engl J Med*. 2022;386(20):1955-1956. doi:10.1056/NEJMc2201761

6. World Health Organization. *Global Status Report on Violence Prevention 2014*. World Health Organization; 2014.

7. Davies FC, Coats TJ, Fisher R, Lawrence T, Lecky FE. A profile of suspected child abuse as a subgroup of major trauma patients. *Emerg Med J*. 2015;32(12):921-925. doi:10.1136/emermed-2015-205285

8. Miller TR, Steinbeigle R, Wicks A, Lawrence BA, Barr M, Barr RG. Disability-adjusted life-year burden of abusive head trauma at ages 0-4. *Pediatrics*. 2014;134(6):e1545-e1550. doi:10.1542/peds.2014-1385

9. Jenny C, Hymel KP, Ritzen A, Reinert SE, Hay TC. Analysis of missed cases of abusive head trauma. *JAMA*. 1999;281(7):621-626. doi:10.1001/jama.281.7.621

10. Oral R, Yagmur F, Nashelsky M, Turkmen M, Kirby P. Fatal abusive head trauma cases: consequence of medical staff missing milder forms of physical abuse. *Pediatr Emerg Care*. 2008;24(12):816-821. doi:10.1097/PEC.0b013e31818e9f5d

11. Adamsbaum C, Grabar S, Mejean N, Rey-Salmon C. Abusive head trauma: judicial admissions highlight violent and repetitive shaking. *Pediatrics*. 2010;126(3):546-555. doi:10.1542/peds.2009-3647

12. Rubin DM, Christian CW, Bilaniuk LT, Zazyczny KA, Durbin DR. Occult head injury in high-risk abused children. *Pediatrics*. 2003;111(6, pt 1):1382-1386. doi:10.1542/peds.111.6.1382

© 2023 American Medical Association. All rights reserved.

Downloaded From: https://edhub.ama-assn.org/ by University of Texas - Rio Grande Valley, Stanley Fisch on 06/01/2023

13. Pawlik MC, Kemp A, Maguire S, Nuttall D, Feldman KW, Lindberg DM; ExSTRA investigators. Children with burns referred for child abuse evaluation: burn characteristics and co-existent injuries. *Child Abuse Negl*. 2016;55:52-61. doi:10.1016/j.chiabu.2016.03.006

14. Kisely S, Strathearn L, Najman JM. Risk factors for maltreatment in siblings of abused children. *Pediatrics*. 2021;147(5):e2020036004. doi:10.1542/peds.2020-036004

15. Lindberg DM, Blood EA, Campbell KA, Laskey AL, Berger RP; Examining Siblings to Recognize Abuse Study Group. Predictors of screening and injury in contacts of physically abused children. *J Pediatr*. 2013;163(3):730-735.e1-3. doi:10.1016/j.jpeds.2013.02.051

16. Hamilton-Giachritsis CE, Browne KD. A retrospective study of risk to siblings in abusing families. *J Fam Psychol*. 2005;19(4):619-624. doi:10.1037/0893-3200.19.4.619

17. Lindberg DM, Shapiro RA, Laskey AL, Pallin DJ, Blood EA, Berger RP; ExSTRA Investigators. Prevalence of abusive injuries in siblings and household contacts of physically abused children. *Pediatrics*. 2012;130(2):193-201. doi:10.1542/peds.2012-0085

18. Becker JC, Liersch R, Tautz C, Schlueter B, Andler W. Shaken baby syndrome: report on four pairs of twins. *Child Abuse Negl*. 1998;22(9):931-937. doi:10.1016/S0145-2134(98)00069-6

19. Schnitzer PG, Ewigman BG. Child deaths resulting from inflicted injuries: household risk factors and perpetrator characteristics. *Pediatrics*. 2005;116(5):e687-e693. doi:10.1542/peds.2005-0296

20. Krug EG, Dahlberg LL, Mercy JA, Zwi AB, Lozano R, eds. *World Report on Violence and Health*. World Health Organization; 2002.

21. Blangis F, Allali S, Cohen JF, et al; European Confederation of Primary Care Paediatricians (ECPCP) research group. Variations in guidelines for diagnosis of child physical abuse in high-income countries: a systematic review. *JAMA Netw Open*. 2021;4(11):e2129068-e2129068. doi:10.1001/jamanetworkopen.2021.29068

22. Campbell KA, Bogen DL, Berger RP. The other children: a survey of child abuse physicians on the medical evaluation of children living with a physically abused child. *Arch Pediatr Adolesc Med*. 2006;160(12):1241-1246. doi:10.1001/archpedi.160.12.1241

23. Campbell KA, Squires J, Cook LJ, Berger RP. Disparities in the medical examination of children in the home of a child with suspected physical abuse. *Child Abuse Negl*. 2009;33(9):612-617. doi:10.1016/j.chiabu.2009.02.008

24. Mankad K, Sidpra J, Oates AJ, Calder A, Offiah AC, Choudhary A. Sibling screening in suspected abusive head trauma: a proposed guideline. *Pediatr Radiol*. 2021;51(6):872-875. doi:10.1007/s00247-020-04917-5

25. Wootton-Gorges SL, Soares BP, Alazraki AL, et al; Expert Panel on Pediatric Imaging. ACR Appropriateness Criteria® suspected physical abuse-child. *J Am Coll Radiol*. 2017;14(5S):S338-S349. doi:10.1016/j.jacr.2017.01.036

26. Choudhary AK, Servaes S, Slovis TL, et al. Consensus statement on abusive head trauma in infants and young children. *Pediatr Radiol*. 2018;48(8):1048-1065. doi:10.1007/s00247-018-4149-1

27. Offiah AC, Adamsbaum C, van Rijn RR. ESPR adopts British guidelines for imaging in suspected non-accidental injury as the European standard. *Pediatr Radiol*. 2014;44(11):1338. doi:10.1007/s00247-014-3153-3

28. The Royal College of Radiologists; The Society and College of Radiographers. *The Radiological Investigation of Suspected Physical Abuse in Children*. The Royal College of Radiologists; 2018.

29. Dalkey N, Helmer O. An experimental application of the DELPHI method to the use of experts. *Manage Sci*. 1963;9(3):458-467. doi:10.1287/mnsc.9.3.458

30. Christian CW; Committee on Child Abuse and Neglect, American Academy of Pediatrics. The evaluation of suspected child physical abuse. *Pediatrics*. 2015;135(5):e1337-e1354. doi:10.1542/peds.2015-0356

31. Kellogg N; American Academy of Pediatrics Committee on Child Abuse and Neglect. Oral and dental aspects of child abuse and neglect. *Pediatrics*. 2005;116(6):1565-1568. doi:10.1542/peds.2005-2315

32. Maguire S, Mann MK, Sibert J, Kemp A. Are there patterns of bruising in childhood which are diagnostic or suggestive of abuse? a systematic review. *Arch Dis Child*. 2005;90(2):182-186. doi:10.1136/adc.2003.044065

33. Parks S, Sugerman D, Xu L, Coronado V. Characteristics of non-fatal abusive head trauma among children in the USA, 2003–2008: application of the CDC operational case definition to national hospital inpatient data. *Inj Prev*. 2012;18(6):392-398. doi:10.1136/injuryprev-2011-040234

34. Oates AJ, Sidpra J, Mankad K. Parenchymal brain injuries in abusive head trauma. *Pediatr Radiol*. 2021;51(6):898-910. doi:10.1007/s00247-021-04981-5

35. Royal College of Paediatrics and Child Health. *Child Protection Evidence: Systematic Review on Fractures*. Royal College of Paediatrics and Child Health; 2018.

36. Bajaj M, Offiah AC. Imaging in suspected child abuse: necessity or radiation hazard? *Arch Dis Child*. 2015;100(12):1163-1168. doi:10.1136/archdischild-2015-308418

37. Lindberg DM, Berger RP, Reynolds MS, Alwan RM, Harper NS; Examining Siblings To Recognize Abuse Investigators. Yield of skeletal survey by age in children referred to abuse specialists. *J Pediatr*. 2014;164(6):1268-73.e1. doi:10.1016/j.jpeds.2014.01.068

38. Merten DF, Radkowski MA, Leonidas JC. The abused child: a radiological reappraisal. *Radiology*. 1983;146(2):377-381. doi:10.1148/radiology.146.2.6849085

39. Belfer RA, Klein BL, Orr L. Use of the skeletal survey in the evaluation of child maltreatment. *Am J Emerg Med*. 2001;19(2):122-124. doi:10.1053/ajem.2001.21345

40. Duffy SO, Squires J, Fromkin JB, Berger RP. Use of skeletal surveys to evaluate for physical abuse: analysis of 703 consecutive skeletal surveys. *Pediatrics*. 2011;127(1):e47-e52. doi:10.1542/peds.2010-0298

41. Ellerstein NS, Norris KJ. Value of radiologic skeletal survey in assessment of abused children. *Pediatrics*. 1984;74(6):1075-1078. doi:10.1542/peds.74.6.1075

42. Scharf RJ, Scharf GJ, Stroustrup A. Developmental milestones. *Pediatr Rev*. 2016;37(1):25-37. doi:10.1542/pir.2014-0103

43. Uffmann M, Schaefer-Prokop C. Digital radiography: the balance between image quality and required radiation dose. *Eur J Radiol*. 2009;72(2):202-208. doi:10.1016/j.ejrad.2009.05.060

44. McNamara CR, Panigrahy A, Sheetz M, Berger RP. The likelihood of an occult fracture in skeletal surveys obtained in children more than 2 years old with concerns of physical abuse. *Pediatr Emerg Care*. 2022;38(2):e488-e492. doi:10.1097/PEC.0000000000002440

45. Pearce MS, Salotti JA, Little MP, et al. Radiation exposure from CT scans in childhood and subsequent risk of leukaemia and brain tumours: a retrospective cohort study. *Lancet*. 2012;380(9840):499-505. doi:10.1016/S0140-6736(12)60815-0

46. Miglioretti DL, Johnson E, Williams A, et al. The use of computed tomography in pediatrics and the associated radiation exposure and estimated cancer risk. *JAMA Pediatr*. 2013;167(8):700-707. doi:10.1001/jamapediatrics.2013.311

47. Lindberg DM, Stence NV, Grubenhoff JA, et al. Feasibility and accuracy of fast MRI versus CT for traumatic brain injury in young children. *Pediatrics*. 2019;144(4):e20190419. doi:10.1542/peds.2019-0419

48. Kemp AM, Rajaram S, Mann M, et al; Welsh Child Protection Systematic Review Group. What neuroimaging should be performed in children in whom inflicted brain injury (iBI) is suspected? a systematic review. *Clin Radiol*. 2009;64(5):473-483. doi:10.1016/j.crad.2008.11.011

49. Choudhary AK, Bradford RK, Dias MS, Moore GJ, Boal DK. Spinal subdural hemorrhage in abusive head trauma: a retrospective study. *Radiology*. 2012;262(1):216-223. doi:10.1148/radiol.11102390

50. Royal College of Paediatrics and Child Health. *Child Protection Evidence: Systematic Review on Head and Spinal Injuries*. Royal College of Paediatrics and Child Health; 2019.

51. Boehnke M, Mirsky D, Stence N, Stanley RM, Lindberg DM; ExSTRA investigators. Occult head injury is common in children with concern for physical abuse. *Pediatr Radiol*. 2018;48(8):1123-1129. doi:10.1007/s00247-018-4128-6

52. Zuccoli G, Panigrahy A, Haldipur A, et al. Susceptibility weighted imaging depicts retinal hemorrhages in abusive head trauma. *Neuroradiology*. 2013;55(7):889-893. doi:10.1007/s00234-013-1180-7

53. Royal College of Paediatrics and Child Health. *Child Protection Evidence: Systematic Review on Retinal Findings*. Royal College of Paediatrics and Child Health; 2015.

54. Sidpra J, Chhabda S, Oates AJ, Bhatia A, Blaser SI, Mankad K. Abusive head trauma: neuroimaging mimics and diagnostic complexities. *Pediatr Radiol*. 2021;51(6):947-965. doi:10.1007/s00247-020-04940-6

55. Kralik SF, Yasrebi M, Supakul N, et al. Diagnostic performance of ultrafast brain MRI for evaluation of abusive head trauma. *AJNR Am J Neuroradiol*. 2017;38(4):807-813. doi:10.3174/ajnr.A5093

© 2023 American Medical Association. All rights reserved.

Downloaded From: https://edhub.ama-assn.org/ by University of Texas - Rio Grande Valley, Stanley Fisch on 06/01/2023

56. Kleinman PK, ed. *Diagnostic Imaging of Child Abuse*. 3rd ed. Cambridge University Press; 2015. doi:10.1017/CBO9780511862366

57. Rabbitt AL, Kelly TG, Yan K, Zhang J, Bretl DA, Quijano CV. Characteristics associated with spine injury on magnetic resonance imaging in children evaluated for abusive head trauma. *Pediatr Radiol*. 2020;50(1):83-97. doi:10.1007/s00247-019-04517-y

58. Choudhary AK, Ishak R, Zacharia TT, Dias MS. Imaging of spinal injury in abusive head trauma: a retrospective study. *Pediatr Radiol*. 2014;44(9):1130-1140. doi:10.1007/s00247-014-2959-3

59. Choudhary AK, Bradford RK, Dias MS, Moore GJ, Boal DKB. Spinal subdural hemorrhage in abusive head trauma: a retrospective study. *Radiology*. 2012;262(1):216-223. doi:10.1148/radiol.11102390

60. Karmazyn B, Reher TA, Supakul N, et al. Whole-spine MRI in children with suspected abusive head trauma. *AJR Am J Roentgenol*. 2022;218(6):1074-1087. doi:10.2214/AJR.21.26674

61. Artunduaga M, Liu CA, Morin CE, et al. Safety challenges related to the use of sedation and general anesthesia in pediatric patients undergoing magnetic resonance imaging examinations. *Pediatr Radiol*. 2021;51(5):724-735. doi:10.1007/s00247-021-05044-5

62. Noguchi K, Seto H, Kamisaki Y, Tomizawa G, Toyoshima S, Watanabe N. Comparison of fluid-attenuated inversion-recovery MR imaging with CT in a simulated model of acute subarachnoid hemorrhage. *AJNR Am J Neuroradiol*. 2000;21(5):923-927.

63. Sigmund GA, Tong KA, Nickerson JP, Wall CJ, Oyoyo U, Ashwal S. Multimodality comparison of neuroimaging in pediatric traumatic brain injury. *Pediatr Neurol*. 2007;36(4):217-226. doi:10.1016/j.pediatrneurol.2007.01.003

64. Bradford R, Choudhary AK, Dias MS. Serial neuroimaging in infants with abusive head trauma: timing abusive injuries. *J Neurosurg Pediatr*. 2013;12(2):110-119. doi:10.3171/2013.4.PEDS12596

65. Sidpra J, Jeelani NUO, Ong J, Birch W, Mankad K. Skull fractures in abusive head trauma: a single centre experience and review of the literature. *Childs Nerv Syst*. 2021;37(3):919-929.

66. Sanchez T, Stewart D, Walvick M, Swischuk L. Skull fracture vs. accessory sutures: how can we tell the difference? *Emerg Radiol*. 2010;17(5):413-418. doi:10.1007/s10140-010-0877-8

67. Prabhu SP, Newton AW, Perez-Rossello JM, Kleinman PK. Three-dimensional skull models as a problem-solving tool in suspected child abuse. *Pediatr Radiol*. 2013;43(5):575-581. doi:10.1007/s00247-012-2546-4

68. Langford S, Panigrahy A, Narayanan S, et al. Multiplanar reconstructed CT images increased depiction of intracranial hemorrhages in pediatric head trauma. *Neuroradiology*. 2015;57(12):1263-1268. doi:10.1007/s00234-015-1584-7

69. Martin A, Paddock M, Johns CS, et al. Avoiding skull radiographs in infants with suspected inflicted injury who also undergo head CT: "a no-brainer?". *Eur Radiol*. 2020;30(3):1480-1487. doi:10.1007/s00330-019-06579-w

70. Kleinman PK, Nimkin K, Spevak MR, et al. Follow-up skeletal surveys in suspected child abuse. *AJR Am J Roentgenol*. 1996;167(4):893-896. doi:10.2214/ajr.167.4.8819377

71. Karmazyn B, Marine MB, Wanner MR, Sağlam D, Jennings SG, Hibbard RA. Establishing signs for acute and healing phases of distal tibial classic metaphyseal lesions. *Pediatr Radiol*. 2020;50(5):715-725. doi:10.1007/s00247-020-04615-2

72. Cumming WA. Neonatal skeletal fractures. birth trauma or child abuse? *J Can Assoc Radiol*. 1979;30(1):30-33.

73. Hansen KK, Keeshin BR, Flaherty E, et al. Sensitivity of the limited view follow-up skeletal survey. *Pediatrics*. 2014;134(2):242-248. doi:10.1542/peds.2013-4024

74. Jenny C. Supporting paediatricians who work in child maltreatment. *Lancet*. 2009;373(9659):195-197. doi:10.1016/S0140-6736(08)61703-1

© 2023 American Medical Association. All rights reserved.

Downloaded From: https://edhub.ama-assn.org/ by University of Texas - Rio Grande Valley, Stanley Fisch on 06/01/2023